

## EP CASE REPORT

# Sound wave balloon-assisted device implantation: a novel approach that merits consideration

Walid Barake<sup>1\*</sup>, Malini Madhavan<sup>1</sup>, Gurukripa N. Kowligi<sup>1</sup>, Yong-Mei Cha<sup>1</sup>, Samuel J. Asirvatham<sup>1,2</sup>, and Paul A. Friedman<sup>1</sup>

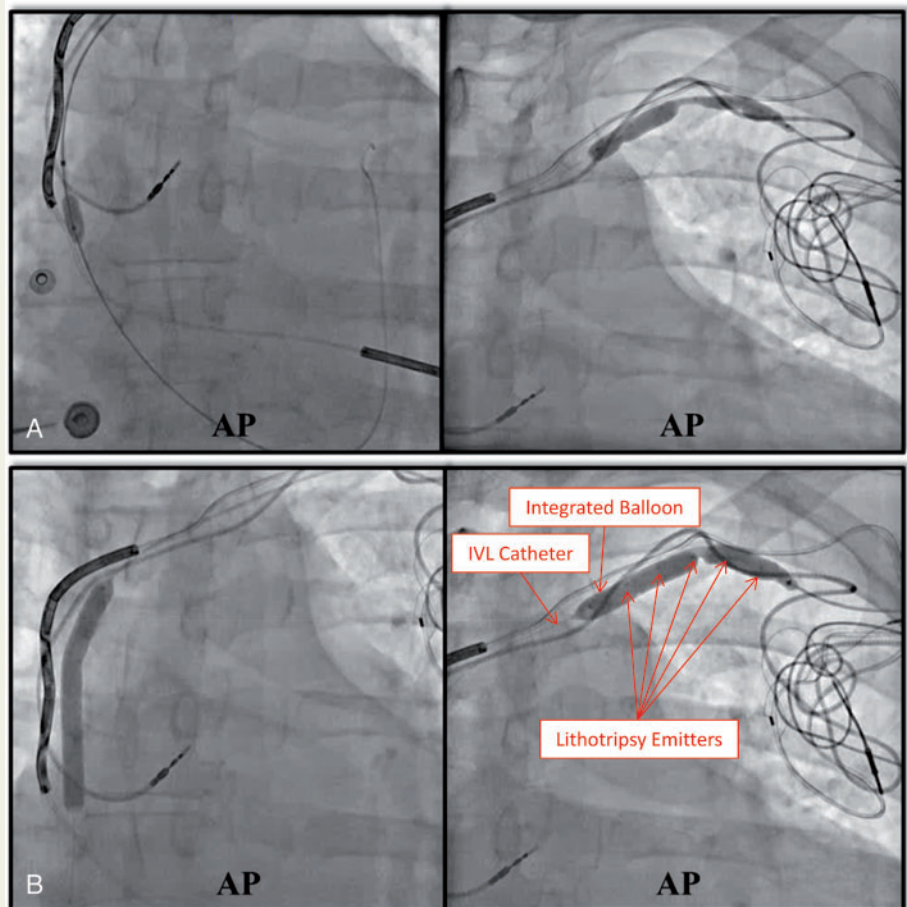
<sup>1</sup>Department of Cardiovascular Diseases, Mayo Clinic, 200 First St SW, Rochester, MN 55905, USA; and <sup>2</sup>Department of Pediatric and Adolescent Medicine, Division of Pediatric Cardiology, Mayo Clinic College of Medicine, 200 First St SW, Rochester, MN 55905, USA

\* Corresponding author. Tel: 507-255-2502. Email address: wbarake@ualberta.ca

A 68-year-old man with dilated cardiomyopathy, atrial fibrillation, atrio-ventricular node ablation, and cardiac resynchronization therapy presented with progressive heart failure and left ventricular (LV) lead dislodgement. Lead revision was undertaken due to LV ejection fraction decline.

Left axillary venography showed occlusion (Supplementary material online, Cine S1). Venous access was unsuccessful. Using a 0.014" Whisper<sup>®</sup> wire (Abbott), the existing LV lead was removed. The wire was then exchanged to Amplatz Extra-Stiff wire (Cook). Attempts to dilate the vein were met with resistance. Venoplasty was attempted using a 6 mm non-compliant balloon (OPTA<sup>®</sup>Pro, Cordis) followed by Flextome cutting-balloon (Boston Scientific) with minimal lumen expansion (Supplementary material online, Cine S2). The lead delivery sheath could not be advanced. Alternative options, including LV endocardial pacing and right-sided system, were considered. We felt, however, that calcifications remain a barrier for right-sided system given the unsuccessful venoplasty of the superior vena cava stenosis (Supplementary material online, Cine-S2.A). The patient had a strong preference to keep the system on the left side. He did not qualify for LV endocardial pacing. We decided to use intravascular lithotripsy (Shockwave<sup>®</sup> balloon.©Shockwave Medical).

The Amplatz wire was exchanged for 0.014" wire to guide the Shockwave-balloon (5 mm × 60 mm). The balloon was used to pre-dilate each lesion by expansion to near-burst pressure. The balloon was then expanded to 4 atm; shockwaves were delivered for a total



**Figure 1** (A) Severely stenotic lesions despite the multiple venoplasty attempts described (prior to sound-wave delivery). The lower panel (B) shows the excellent venoplasty results with shockwave therapy except for a residual 50% stenosis at the clavicular level. AP, antero-posterior; IVL, intravascular lithotripsy.

treatment of 300 s (proximal-to-distal). Sound-waves cracked most calcifications with desirable angioplasty results except the lesion at the clavicle level which remained moderately stenotic (Figure 1). The delivery sheath was then easily advanced and His-bundle lead was fixated with a paced QRS duration of 100 ms. In follow-up, the patient did very well with stable lead parameters (peri-operative and follow-up parameters) and no heart failure or complications.

## Discussion

Calcification leading to vein stenosis poses significant challenges to lead revision/extraction. We describe a novel approach using ultrasound-based therapy to assist in lead management. Sound-waves have been widely used for urinary stones disruption.<sup>1</sup> More recently, ultrasound-enhanced therapy was Food and Drug Administration (FDA)-cleared to treat peripheral arterial lesions.<sup>2</sup> It is not currently FDA-approved for venoplasty. Sound-waves create localized field-effect that preferentially affects vessel wall calcium. Current tools may not address calcification effectively. Mechanical extraction disturbs those calcifications but at the expense of vascular/lead trauma. The risk of arrhythmia or device-system interference/damage imposed by shockwaves is currently unknown. The rhythm should be carefully monitored during shockwaves delivery. Although rare, shockwaves have been reported to cause depolarization affecting cardiac rhythm.<sup>3</sup> This unique lead management technology warrants future study.

## Supplementary material

Supplementary material is available at *Europace* online.

**Conflict of interest:** none declared.

## References

1. Chaussy C, Brendel W, Schmiedt E. Extracorporeally induced destruction of kidney stones by shock waves. *Lancet* 1980;**2**:1265–8.
2. Shockwave Medical, Inc. Shockwave Medical Intravascular Lithotripsy (IVL) system; U.S. Food and Drug Administration. [https://www.accessdata.fda.gov/cdrh\\_docs/pdf18/K180958.pdf](https://www.accessdata.fda.gov/cdrh_docs/pdf18/K180958.pdf) (26 July 2018, date last accessed).
3. McQuillan C, Alkhalil M, Johnston PW. A paced heart without a pacemaker. *Eur Heart J* 2019;**40**:819a.